

ALTERED CAST TECHNIQUE: IMPROVING TISSUE SUPPORT FOR THE DISTAL EXTENSION BASES



Haroon Rashid¹ BDS, MDSc

Fahim Ahmed Vohra² BDS, MDSc

Amir Shahzad² BDS

Altered cast impression technique is commonly used for the mandibular distal extension partially edentulous arches. The technique is relatively simple but requires increased chair-side time and laboratory cost. Oral tissues that have been displaced during the impression procedure attempt to regain the anatomic form and they may get inflamed if the denture base does not permit them to do so. The aim of this case report is to portray an approach of recording a minimal tissue displacing altered cast impression using addition cured silicone material.

KEYWORDS: Distal extension bases, Stability, Addition Cured Silicones, Altered Cast Technique, Corrected Cast Technique

HOW TO CITE: Rashid H, Vohra FA, Shahzad A. Altered Cast Technique: Improving Tissue Support for the Distal Extension Bases. J Pak Dent Assoc 2013; 22: 234-236.

INTRODUCTION

Distal extension removable partial denture (RPD) depends largely on the residual alveolar ridge for support, stability and retention. These dentures only have partial support from teeth as their bases may be the extensions covering the ridge distal to the last abutment tooth. The tooth supported RPDs have an advantage of presence of a direct retainer whereas this is lacking in the prosthesis fabricated over distal extension bases. Support from the residual alveolar ridge as described by Carr and Brown (1) will depend on several factors which include the quality of the residual alveolar ridge and its contour, extent of the ridge covered by the RPD, the accuracy of the impression, fitting accuracy of the denture, RPD design and the total occlusal load applied during function.

An altered cast impression procedure to improve the support of distal extension removable partial dentures is widely taught, but not often used in dental practice (2). Also known as the corrected-cast technique (3) the technique requires an additional step for both the dentist and the dental technician. It offers several advantages which include maximum stability, minimal stress on abutment teeth, and more predictable occlusion (3). Other benefits include reduction of the number of post operative visits, preservation of the residual ridges and decreasing the food

impaction. The following paper outlines a quick and easy technique for constructing an altered cast for an RPD.

CASE REPORT

A 53 year old medically stable female patient attended the outpatient department of Ziauddin College of dentistry complaining of missing posterior teeth in the lower arch. The patient was wearing an acrylic partial denture which was loose and ill fitting. The denture had inadequate base extensions and poor tissue adaptation due to which there were signs of minor trauma to the soft tissue covering the crest of the alveolar ridge. No further signs of abnormalities were detected during intra-oral and extra-oral examination and it was decided that a new cast partial denture (CPD) is provided to the patient using the altered-cast technique once tissue healing is adequate. Option of implant retained fixed partial dentures was given to the patient but the patient could not afford the expense of the treatment. The patient decided to pursue the treatment plan which included the fabrication of a lower CPD. A step by step procedure is outlined with reference to various clinical and laboratory stages during the treatment:

Stage 1:

Maxillary and mandibular impressions were obtained using irreversible hydrocolloid (Cavex CA37?, Holland BV) and upper and lower study casts were obtained. Mandibular study casts were placed on a stage of a dental surveyor and surveying was carried out after which the design of the cast metal framework was finalized.

1. Assistant Professor, Department of Prosthodontics, Ziauddin College of Dentistry, Karachi, Pakistan.

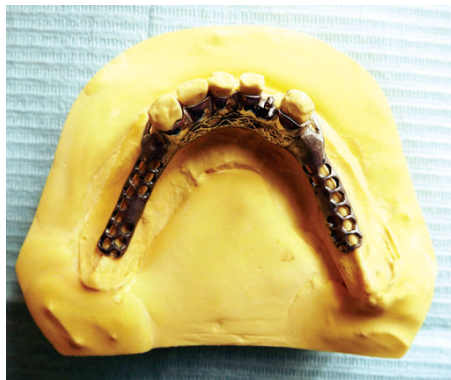2. Assistant Professor, Department of Prosthodontics, King Saud University, Saudi Arabia.

3. Ziauddin College of Dentistry, Karachi, Pakistan.

Correspondence to: "Dr. Haroon Rashid Baloch" <haroon.rashid@zu.edu.pk>

Stage 2:

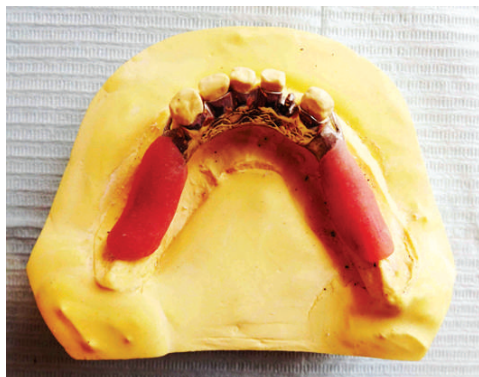Mouth preparation was done intraorally and final impressions of both the arches were recorded using medium bodied addition cured silicone (Zhermack Elite Monophase) using custom made trays. Master casts were obtained and design finalized. Investing and casting procedures were performed in the laboratory and the completed framework was checked to ensure that it fits the casts accurately (Fig 1).



-1- Mandibular metal framework

Stage 3:

The cast metal framework was tried intra-orally for accuracy of fit and once this was done, an acrylic resin custom made trays were fabricated to the mandibular framework (Fig 2.). Border



-2- Acrylic resin tray attached to metal framework



3- Border moulded tray

moulding was performed using green stick tracing compound (Fig 3). (Metrodent tracing sticks). Tray adhesive (Cauk tray adhesive, Dentsply) was applied over the impression surface of the tray and the final impression was taken using light bodied silicone (3M ESPE Express). During seating of the loaded tray, gentle finger pressure was applied over the areas of the framework which only came in contact with the teeth and not to the tray itself (Fig 4). It was ensured that the framework remained stable and did not move until the impression material was set.



-4- Final Impression with light bodied silicone

Stage 4:

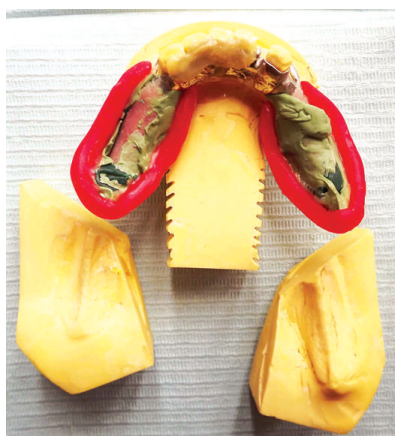
This was the stage when cast was altered in the laboratory. Beading of the final impression was done (Fig 5) and two saw cuts on the cast were made perpendicular to each other on either side of the saddle areas (Fig 6). Grooves were placed on the cut surface of the cast so that retention of the newly poured stone could be improved. The framework was seated completely on the cast, fixed using sticky wax and boxing procedure was performed (Fig 7). The final impression was poured using die stone and the working altered cast was removed (Fig 8). The usual remaining steps of denture fabrication were carried out, denture was delivered to the patient and post operative instructions were given.

DISCUSSION


Free end saddles are liable to be displaced under occlusal pressure. This is as a result of the displaceability of the mucosa of the free end saddle. The altered cast technique was a popular technique that was introduced in an attempt to overcome the problem. Oral tissues that have been overly displaced during the impression procedure attempt to regain their anatomic form and if the denture base does not permit them to do this, the tissues become inflamed followed by impaired physiological function. Tissues which are minimally displaced by impression materials respond favorably to the additional load applied. In the current case, it was aimed to improve the tissue support for the distal extension base by minimally displacing the soft tissues during



-5- Final impression with beading



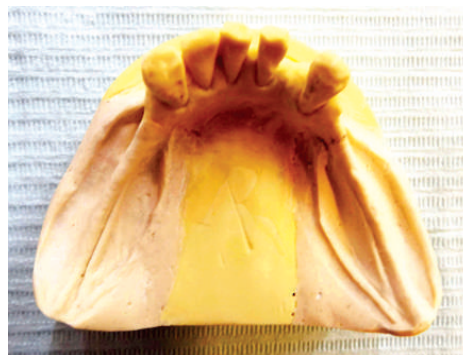-6- Casts with two saw cuts perpendicular to each other



-7- Boxed Impression

the impression procedure.

Zinc oxide eugenol paste or low viscosity silicone is usually placed in the customized tray and the framework is placed into the mouth and the impression taken with pressure only on the support elements of the framework resting on teeth. Low viscosity silicone was preferred over zinc oxide eugenol paste in the current



-8- Working Altered Cast

case because it offers many advantages which include good tear strength, adequate working time, high accuracy, minimal distortion upon removal and excellent dimensional stability(4). However, they are expensive, require tray adhesive prior to their use and are hydrophobic thus; moisture control may be difficult to achieve. Altered cast impression technique is commonly used for the mandibular distal extension partially edentulous arches (Kennedy Class I and Class II). This technique is not common to be used in maxillary arches because the nature of the masticatory mucosa and the amount of form tissue support.

CONCLUSION

The altered cast technique is relatively simple but requires increased chair-side time and laboratory cost. However, considering the benefits of this technique, it is recommended that clinicians should incorporate it in their routine prosthodontic management of specific patients especially in those cases where implant therapy cannot be performed due to medical and dental contraindications.

REFERENCES

1. Carr AB, Brown DT. McCracken's Removable Partial Prosthodontics. 12th Edition. Mosby: 2011. Chapter 16. P 232.
2. Frank RP, Brudvik JS, Noonan CJ. Clinical outcome of the altered cast impression procedure compared with use of a one-piece cast. J Prosthet Dent. 2004 May;91:468-476.
3. Garcia EE, Evans JG. Removable partial dentures: the altered-cast technique. J Dent Technol. 1998;15:25-29.
4. Forrester-Baker L, Seymour KG, Samarawickrama D, Zou L, Cherukara G, Patel M. A comparison of dimensional accuracy between three different addition cured silicone impression materials. Eur J Prosthodont Restor Dent. 2005;13:69-74.